

Safety and Efficacy of Protected Cardiac Intervention: Clinical Evidence for Sentinel Cerebral Embolic Protection

Ulrich Schäfer

Department of General and Interventional Cardiology, University Hospital Eppendorf, Hamburg, Germany

Abstract

Stroke is a well-documented potential risk of structural cardiac interventions. As a result of the far-reaching burden of stroke on patients, caregivers and the healthcare system, new medical interventions and therapies are being developed to help mitigate this risk. One such intervention is the recently FDA-cleared Sentinel™ Cerebral Protection System (Sentinel; Claret Medical, Santa Rosa, CA, USA) designed to capture and remove debris dislodged during transcatheter aortic valve replacement procedures. In the SENTINEL IDE Study, and in a more recent all-comers trial, Sentinel significantly reduced periprocedural strokes by 63 and 70 % respectively. In this paper, we review the growing body of evidence supporting the use of Sentinel in transcatheter aortic valve replacement and other endovascular procedures.

Keywords

Embolic protection, ischemic stroke, transcatheter aortic valve replacement, Sentinel

Disclosure: Ulrich Schäfer received travel support and speakers' honoraria from Claret Medical.

Received: 5 July 2017 **Accepted:** 12 August 2017 **Citation:** *Interventional Cardiology Review* 2017;**12**(2):128–32. DOI: 10.15420/icr.2017:19:2

Correspondence: Ulrich Schäfer, Department of General and Interventional Cardiology, University Heart Centre Hamburg, Martinistraße 52, 20251 Hamburg, Germany. E: u.schaefer@uke.de

As the field of interventional cardiology has grown, so too has interest in mitigating severe adverse outcomes such as stroke. Unfortunately, the risk of stroke is increased by many underlying disease conditions (atrial fibrillation, patent foramen ovale, carotid artery disease and other vascular disease affecting brain perfusion, etc.), making clear differentiation between cardiac intervention-related cerebral infarction and the effect of other coexisting factors very difficult. In this regard, the prevalence of atrial fibrillation in average transcatheter aortic valve replacement (TAVR) patient cohorts has been reported to be over 31 % (9 studies, 285/902 patients)^{1–9} and the prevalence of previous stroke has been reported as high as 10.8 % (14 studies, 111/1028 patients),^{6–14} confounding the attribution of stroke to TAVR procedures.

Covert Central Nervous System Infarction

While clinically overt stroke is one of the most feared adverse events among patients undergoing invasive or interventional procedures, subclinical neurological events or covert central nervous system (CNS) infarctions are also a significant risk. In general, covert CNS infarctions are best detected by diffusion-weighted MRI in the absence of any clinically apparent symptoms. They are prevalent in approximately 20 % of the general population, but the risk and incidence rate increase drastically with age and in populations affected by certain medical conditions (see above), as well as following interventional and surgical procedures. The incidence of new lesions following TAVR, for instance, is estimated to be 68–91 %, with at least one study demonstrating evidence of new cerebral infarctions in 100 % of patients.¹⁶ As with clinically overt stroke, substantial evidence has shown that the presence of covert cerebral infarctions increases the risk of future stroke, cognitive decline, dementia and mortality. The same applies for surgical aortic valve interventions where even larger brain infarctions are seen.^{17–21}

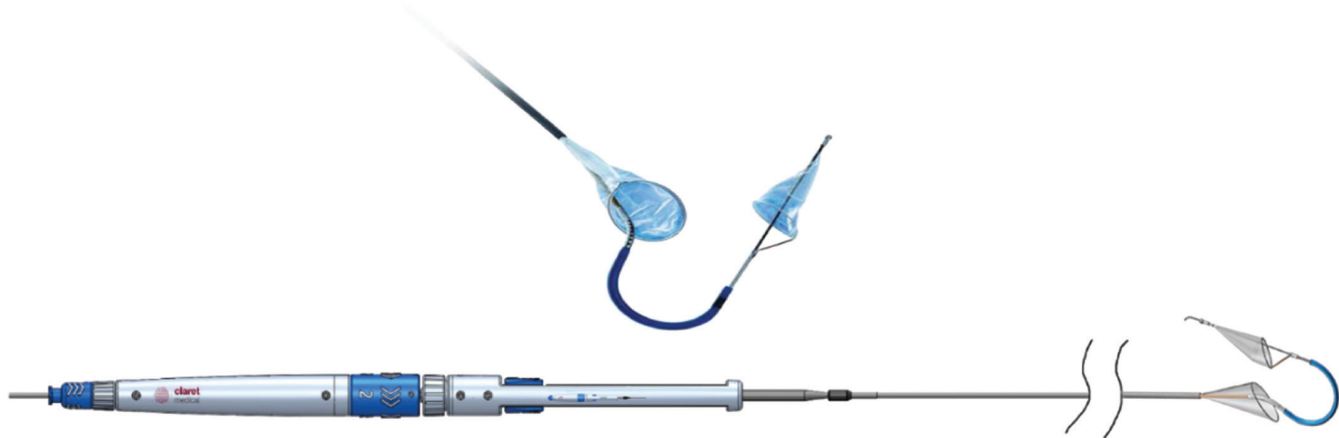Stroke Burden

Stroke from any cause poses a tremendous strain on a patient, their family and the healthcare system. Hospitalisation due to stroke is costly, and continued expenditures including inpatient care, rehabilitation and long-term care exceed US \$140,000 over a lifetime.²² Recent studies also conclude that these costs increase greatly with increased stroke severity and resulting disability.^{22,23}

TAVR and Stroke

In the last 15 years, TAVR has emerged as an important therapeutic option for patients with severe aortic stenosis, particularly those at increased risk of operative mortality or morbidity with traditional surgical aortic valve replacement (SAVR).^{24–28} Although TAVR has consistently demonstrated similar or better outcomes than SAVR,^{24–29} neurological complications remain a concern. Early in the TAVR experience, reports of clinical stroke rates up to 5 %, mainly occurring within 1 week of the procedure, garnered significant attention, and have been shown to be associated with lower 1-year survival rates.¹¹ As TAVR populations, procedures and devices have matured, reported rates of overt clinical stroke within controlled clinical trials,²⁹ and in real-world practice, remain a critical health issue. Newer, repositionable TAVR devices allow for more precise valve implantation, but this may be at the expense of higher embolic burdens, increasing the risk for stroke and death.²¹ In fact, the STS/ACC Transcatheter Valve Therapy Registry (TVT Registry), designed to benchmark safety and efficacy outcomes related to US commercial TVT procedures (>53,000 cases to date), showed no significant decline in 30-day site reported stroke rates from 2012 (2.6 %) to 2015 (2.2 %) despite new evolutions in TAVR devices.¹¹ The TVT Registry also highlighted that stroke risk is independent of increased physician TAVR experience. This finding is corroborated by a multinational registry of over 1,900 subjects

Figure 1: An Example of the Sentinel Device



Source: Claret Medical, 2017.

in 80 international centres.³⁰ It is important to emphasise that the TVT Registry collects information on site reported strokes, which does not require diagnosis of a stroke by a certified neurologist, thus likely underestimating the true stroke rate in the real-world setting. Further confounding the true stroke rate, the definition and classification of stroke has been controversial and has changed over the last decade.²¹

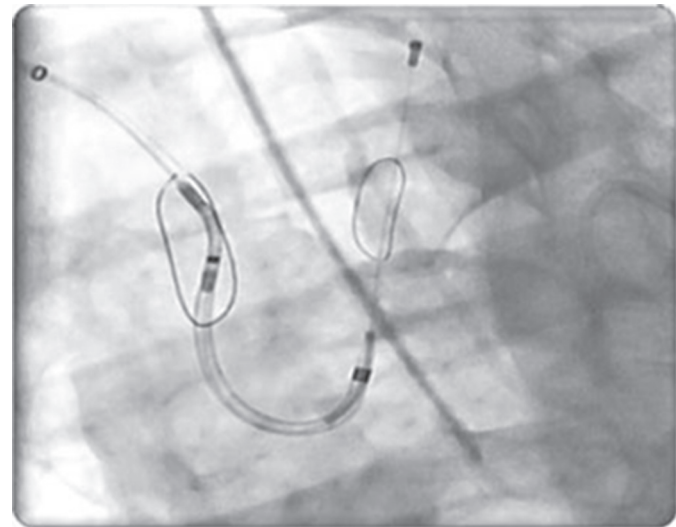
As mentioned above, procedure-related stroke or new ischemic cerebral infarctions may result from a variety of patient- and disease-related causes such as severity of atherosclerosis, age, gender, hyperlipidaemia, history of atrial fibrillation and/or technical aspects of the procedure itself, including mechanical manipulation of instruments or interventional devices. A rapidly growing body of clinical evidence shows that embolic debris is generated in the vast majority of patients undergoing TAVR.¹² Debris can be up to 1 cm in size, is from a variety of vascular and valvular tissue sources, and has been captured during the use of a variety of different transcatheter valves and interventional approaches.¹

Sentinel

Sentinel™ Cerebral Protection System (Claret Medical, Santa Rosa, CA, USA) is designed to protect the brain from the risk of stroke by filtering, capturing and removing debris dislodged during many interventional and surgical left heart, as well as endovascular, procedures. The device consists of two filters within a single 6 French delivery catheter percutaneously placed from the right radial (preferred) or brachial artery over a 0.014" guide wire. The filters are deployed in the brachiocephalic and the left common carotid arteries, the two main arteries supplying the brain, and are withdrawn into the catheter at the conclusion of the procedure (*Figures 1 and 2*).

Since the initial proof of concept study in 2011, numerous manuscripts or presentations describing experience with Sentinel have been published. Sentinel has shown procedural success of greater than 90 % across multiple studies and therapies, which is paralleled by its strong safety profile (*Table 1*).^{1-3,12-15} Although MRI imaging evidence in terms of reduced lesion number and volume is variable across studies,^{2,3,13} detailed histopathological assessments have described near ubiquitous, and remarkably consistent, capture of a wide variety of debris types within the filters (*Figure 2*). Not surprisingly, due to the success experienced with Sentinel in TAVR procedures, other structural interventions known to be cardioembolic, including mitral valve interventions (MitraClip),³¹ left atrial appendage occlusion procedures

Figure 2: Example of the Sentinel Device in situ



Source: Claret Medical, 2017.

(LAO)³² and thoracic endovascular aneurysm repair (TEVAR),^{33,34} have shown remarkably similar patterns of debris capture and procedural success with the use of cerebral embolic protection (CEP).

Patient Population

The Sentinel device was originally conceived as an adjunctive therapy for TAVR; thus, the majority of published studies have been conducted in patients with severe, symptomatic aortic stenosis undergoing TAVR. To date, studies of Sentinel in conjunction with TAVR therapy have been conducted in similar patient populations, which makes comparisons and data pooling between studies possible. Indeed, although the current literature summary does not include any formal Sentinel-specific meta-analysis, a review and meta-analysis of cerebral embolic protection trials, including SENTINEL, has been published.³⁵

Overall, patients included in studies of Sentinel with TAVR to date have been elderly and at increased risk of surgical mortality and morbidity (including perioperative stroke) based on traditional surgical risk scores such as the Society of Thoracic Surgeons and the Logistic EuroSCORE. Importantly, studies that have included baseline MRI imaging have found a wide range of pre-existing T2/FLAIR lesion volume, indicating

Table 1: Sentinel Studies with TAVR

Safety and Procedural Success	MISTRAL-I, Source: Van Mieghem, et al., 2013	Source: Van Mieghem, et al., 2015	MISTRAL-C, Source: Van Mieghem, et al., 2016 ^c	CLEAN-TAVI, Source: Haussig, et al., 2016 ^c	SENTINEL-IDE, Source: Kapadia, et al., 2016	ALSTER, Source: Schmidt, et al., 2016	CSI-Ulm-TAVR Study, Source: Wohrle, 2017
Study/Therapy	TAVR-Histo	TAVR	TAVR	TAVR	TAVR	TAVR-Histological	TAVR
Study Type	Prospective, single arm	Prospective, single arm	Randomised, clinical trial	Randomised, clinical trial	Randomised, clinical trial	Prospective, single arm	Prospective, consecutive all comers
Patients (n) ^a	30	81	32	50	234	161	280
Death (n, %)	1 (2.5)	2 (3.0)	1 (3)	0	3 (1.3)	6 (3.7) [note: discharge, not 30-day]	2 (0.7)
Stroke (n, %)	1 (2.5)				13 (5.6)	1 (0.62)	4 (1.4)
Disabling	1 (2.5)	2	0		2 (0.9)		
Non-disabling	0		0		11 (4.8)		
Acute Kidney Injury Stage 3 (n, %)	1 (2.5)				1 (0.4)		3 (1.1) ^b
Major Vascular Complication	4 (10)		0	5 (10)	21 (8.6) ^c		5 (1.8)
Patients with Debris (%)	75	86	100	86 ^d	99	97	
Procedural Success ^e (%)	100	100	94	92	94		99.6

^aNumber of patients and clinical event rates apply specifically to the device-treated arm(s); ^bacute kidney injury stage 2 or 3; ^c1 (0.4 %) radial/brachial, thus device-related; ^dUnpublished data, Renu Virmani, MD, on file with CV Path Institute; ^esuccessful deployment and retrieval of both filters. TAVR = transcatheter aortic valve replacement.

that prior brain injury and gliosis, or white matter disease, are prevalent in this patient population.

In addition to successful use of Sentinel with TAVR, a number of small feasibility studies have shown promise for the use of Sentinel with other endovascular therapies, including LAAO, TEVAR, MitraClip and valve-in-valve procedures.

Safety Outcomes

Given the ease of use of the device and the high procedural success rates, it is not surprising that acute procedural events and 30-day safety events related to the use of Sentinel are rare. Published reports of Sentinel demonstrate consistently low rates of mortality and neurological events, and randomised trials have documented similar major adverse cardiac and cerebrovascular event rates in patients treated with Sentinel (Table 1). In the largest randomised study, SENTINEL, the Sentinel device was easily delivered and was compatible with standard TAVR workflow.¹³ Total procedure time was increased by approximately 13 min, and fluoroscopy time was increased by 3 min.¹³ The safety profile of Sentinel is underscored by a >92 % procedural success rate in more than 866 patients across 11 studies, and for multiple endovascular therapies.^{1,3,5,12,13}

Neurological Events

The 30-day rates of overt neurological events, both stroke and transient ischemic attack, were low across all published studies of the Sentinel device. In the CSI-Ulm trial, the largest consecutively enrolled cohort of Sentinel in a commercial setting (n=802), the overall 7-day stroke rate when Sentinel CEP was used was 1.4 %, representing a statistically significant reduction when compared to a cohort of subjects who did not receive CEP at 4.2 % (p=0.03).³⁶ A similar trend was observed in the randomised SENTINEL study (n=363), wherein the periprocedural (≤72 h) stroke rate for Sentinel-protected patients was reduced by 63 %; 3.0 % for patients protected with Sentinel,

versus 8.2 % (p=0.05) for unprotected patients.³⁷ When considering the more sensitive endpoint of any worsening of the National Institute of Health Stroke Scale, a study-level meta-analysis by Guistino et al. found a strong trend in favour of TAVR with cerebral embolic protection (M-H Risk Ratio 0.55 [0.27, 1.09], p=0.09) further supporting the results observed in both the CSI-Ulm and Sentinel trials.³⁸ These positive trends in stroke reduction are particularly important when considering the numerous studies that have confirmed the occurrence of stroke post-TAVR.

Mortality

Seven studies have reported 30-day mortality after TAVR with Sentinel, with rates ranging from 0 to 3 %. Within the three randomised trials in which TAVR with Sentinel protection was compared to unprotected TAVR, no significant differences in 30-day mortality were observed between the device treatment and control groups, although deaths in the Sentinel groups were consistently numerically lower (Table 1).

In addition to studies focused on the Sentinel device alone, a recent study-level meta-analysis of all randomised control trials for CEP to date found that, as a class, CEP devices showed a decreased risk of stroke and mortality over unprotected TAVR, which corresponded to an approximately 4.0 % reduction in absolute risk.³⁵

Other Clinical Events

Because the deployment and retrieval of the Sentinel device slightly lengthens the TAVR procedure, there was some early concern about potential increases in acute kidney injury. The low rates of Stage 3 acute kidney injury reported in the early Netherlands experience (2.5 %)¹ and SENTINEL Study (0.4 %)¹³ alleviate these concerns. Low rates of bleeding and vascular complications are similarly reassuring. In the SENTINEL Study, only 1 out of 231 patients (0.4 %) experienced a major vascular complication, a pseudoaneurysm, related to brachial access for the Sentinel device.

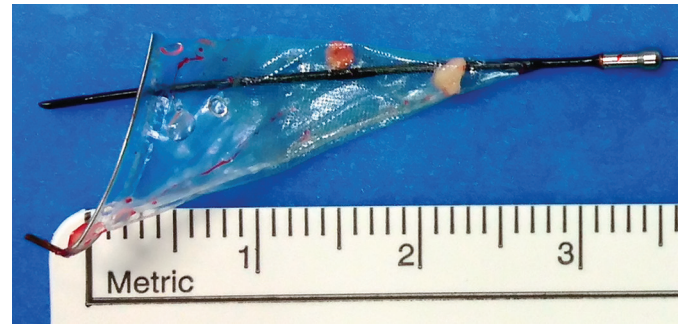
Histopathology and Morphometry

Seven of the published studies, as well as several conference proceedings, have reported histopathological analyses of debris captured by the Sentinel device. The methods for the histopathological analyses were similar across the studies and were performed by the same independent core laboratory. As described previously, regardless of the primary procedure (TAVR, Mitraclip, LAAO, TEVAR), all studies reported near ubiquitous capture of debris removed from the Sentinel device. Rates for debris capture per patient ranged from 75 to 100 % across studies. In order to better understand the prevalence and etiology of the debris captured by the filters, the SENTINEL-H Study was conducted. Sentinel-H was a multicentre, all-comers study of 217 patients in Europe. In accordance with other Sentinel studies, debris was captured in 99 % of patients. As with other Sentinel studies, acute thrombus was found most commonly (85 %), and nearly always in conjunction with tissue-derived material, including arterial wall, valve tissue, calcification and myocardium. Organising/organised thrombus and foreign material were also common.³⁹ In addition to the high rates of debris capture (Figures 3 and 4), the SENTINEL Study discovered that 1 in 4 patients had, on average, 25 particles in their filters that were greater than or equal to 0.5 mm in size.

Conclusion

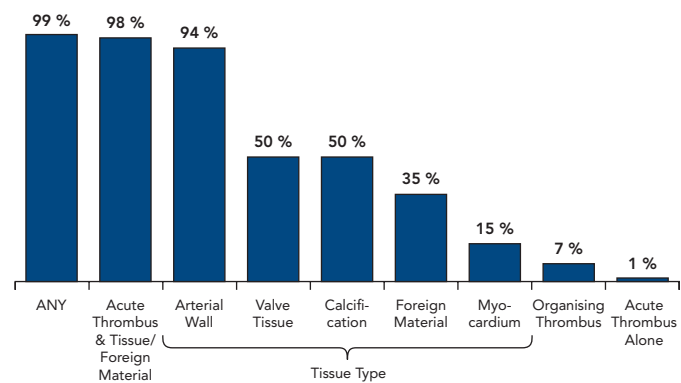
Despite advances in TAVR therapies and techniques, stroke is and will continue to be the Achilles heel of structural heart and endovascular procedures. Indeed, the complexity of discriminating between clinical condition-related strokes and cardiac intervention-related strokes needs further refinement, but all would agree that reducing stroke, regardless of cause, should be a goal. Sentinel is a good step toward that goal. Across multiple studies, Sentinel has demonstrated a strong safety profile and a >92 % procedural success rate. The ease of use of the Sentinel device, combined with minimal disruption to the normal TAVR workflow, make it a viable adjunct therapy that could soon be considered a standard of care for TAVR, and possibly for other cardiac and vascular interventions. Studies to date using Sentinel have been performed in high-risk surgical patients who have an elevated 'background noise' of medical history. However, Sentinel has now been

Figure 3: Example of Debris Captured by Sentinel



Source: Claret Medical, 2017.³⁷

Figure 4: Patients (%) with Debris Captured in the SENTINEL Study



Source: Claret Medical, 2017.³⁷

cleared by the US FDA to be used in all TAVR patients regardless of surgical risk at the same time that TAVR expands to treat moderate- and low-risk patients and potentially asymptomatic aortic stenosis patients. New repositionable TAVR devices facilitate more precise valve implantation but may cause higher embolic burden, which will further emphasise the role of cerebral embolic protection. ■

- Van Mieghem NM, Schipper ME, Ladich E, et al. Histopathology of embolic debris captured during transcatheter aortic valve replacement. *Circulation* 2013;**127**:2194–201. DOI: 10.1161/CIRCULATIONAHA.112.001091; PMID: 23652860
- Van Mieghem NM, van Gils L, Ahmad H, et al. Filter-based cerebral embolic protection with transcatheter aortic valve implantation: the randomised MISTRAL-C trial. *EuroIntervention* 2016;**12**:499–507. DOI: 10.4244/EIJV12I4A84; PMID: 27436602
- Haussig S, Mangner N, Dwyer MG, et al. Effect of a cerebral protection device on brain lesions following transcatheter aortic valve implantation in patients with severe aortic stenosis: the CLEAN-TAVI randomized clinical trial. *JAMA* 2016;**316**:592–601. DOI: 10.1001/jama.2016.10302; PMID: 27532914
- Naber CK, Ghanem A, Abizaid AA, et al. First-in-man use of a novel embolic protection device for patients undergoing transcatheter aortic valve implantation. *EuroIntervention* 2012;**8**:43–50. DOI: 10.4244/EIJV8I1A8; PMID: 22403768
- Schmidt T, Akdag O, Wohlmuth P, et al. Histological findings and predictors of cerebral debris from transcatheter aortic valve replacement: the ALSTER experience. *J Am Heart Assoc* 2016;**5**:e004399. DOI: 10.1161/JAHA.116.004399; PMID: 27930358
- Eggebrecht H, Schermund A, Voigtländer T, et al. Risk of stroke after transcatheter aortic valve implantation (TAVI): a meta-analysis of 10,037 published patients. *EuroIntervention* 2012;**8**:129–38. DOI: 10.4244/EIJV8I1A20; PMID: 22391581
- Nombela-Franco L, Webb JG, de Jaegere PP, et al. Timing, predictive factors, and prognostic value of cerebrovascular events in a large cohort of patients undergoing transcatheter aortic valve implantation. *Circulation* 2012;**126**:3041–53. DOI: 10.1161/CIRCULATIONAHA.112.110981; PMID: 23149669
- Bosmans J, Bleiziffer S, Gerckens U, et al. The incidence and predictors of early- and mid-term clinically relevant neurological events after transcatheter aortic valve replacement in real-world patients. *J Am Coll Cardiol* 2015;**66**:209–17. DOI: 10.1016/j.jacc.2015.05.025; PMID: 26184612
- Kodali SK, Williams MR, Smith CR, et al. Two-year outcomes after transcatheter or surgical aortic-valve replacement. *N Engl J Med* 2012;**366**:1686–95. DOI: 10.1056/NEJMoa1200384; PMID: 22443479
- Kapadia S, Agarwal S, Miller DC, et al. Insights into timing, risk factors, and outcomes of stroke and transient ischemic attack after transcatheter aortic valve replacement in the PARTNER trial (placement of aortic transcatheter valves). *Circ Cardiovasc Interv* 2016;**9**:2 e002981. DOI: 10.1161/CIRCINTERVENTIONS.115.002981; PMID: 27601428
- Holmes DR, Jr, Nishimura RA, Grover FL, et al. Annual outcomes with transcatheter valve therapy: from the STS/ACC TVT registry. *J Am Coll Cardiol* 2015;**66**:2813–23. DOI: 10.1016/j.jacc.2015.10.021; PMID: 26652232
- Van Mieghem NM, El Faquir N, Rahhab Z, et al. Incidence and predictors of debris embolizing to the brain during transcatheter aortic valve implantation. *JACC Cardiovasc Interv* 2015;**8**:718–24. DOI: 10.1016/j.jcin.2015.01.020; PMID: 25946445
- Kapadia SR, Kodali S, Makkar R, et al. Cerebral embolic protection during transcatheter aortic valve replacement. *J Am Coll Cardiol* 2016;**69**:367–77. DOI: 10.1016/j.jacc.2016.10.023; PMID: 27815101
- Schmidt T, Schluter M, Alessandrini H, et al. Histology of debris captured by a cerebral protection system during transcatheter valve-in-valve implantation. *Heart* 2016;**102**:1573–80. DOI: 10.1136/heartjnl-2016-309597; PMID: 27220695
- Gress DR. The problem with asymptomatic cerebral embolic complications in vascular procedures: what if they are not asymptomatic? *J Am Coll Cardiol* 2012;**60**:1614–6. DOI: 10.1016/j.jacc.2012.06.037; PMID: 22999732
- Pagnesi M, Martino EA, Chiarito M, et al. Silent cerebral injury after transcatheter aortic valve implantation and the preventive role of embolic protection devices: A systematic review and meta-analysis. *Int J Cardiol* 2016;**221**:97–106. DOI: 10.1016/j.ijcard.2016.06.143; PMID: 27400304
- Bernick C, Kuller L, Dulberg C, et al. Silent MRI infarcts and the risk of future stroke: the cardiovascular health study. *Neurology* 2001;**57**:1222–9. PMID: 11591840
- Gupta A, Giambrone AE, Gialdini G, et al. Silent brain infarction and risk of future stroke: a systematic review and meta-analysis. *Stroke* 2016;**47**:719–25. DOI: 10.1161/STROKEAHA.115.011889; PMID: 26888534
- Barber PA, Hach S, Tippett LJ, Ross L, Merry AF, Milsom P. Cerebral ischemic lesions on diffusion-weighted imaging are associated with neurocognitive decline after cardiac surgery. *Stroke* 2008;**39**:1427–33. DOI: 10.1161/STROKEAHA.107.502989; PMID: 18323490
- Bokura H, Kobayashi S, Yamaguchi S, et al. Silent brain infarction and subcortical white matter lesions increase the risk of stroke and mortality: a prospective cohort study. *J Stroke Cerebrovasc Dis* 2006;**15**:57–63. DOI: 10.1016/j.jstrokecerebrovasdis.2005.11.001; PMID: 17904049
- Mokin M, Zivadinov R, Dwyer MG, Lazar RM, Hopkins LN, Siddiqui AH. Transcatheter aortic valve replacement: perioperative stroke and beyond. *Expert Rev Neurother* 2017;**17**:327–34. DOI: 10.1080/14737175.2017.1253475; PMID: 27786568
- Ma VY, Chan L, Carruthers, KJ. The incidence, prevalence, costs and impact on disability of common conditions requiring rehabilitation in the US: stroke, spinal cord injury, traumatic brain injury, multiple sclerosis, osteoarthritis, rheumatoid arthritis, limb loss, and back pain. *Arch Phys Med Rehabil* 2014;**95**:986–95. DOI: 10.1016/j.apmr.2013.10.032; PMID: 24462839
- Spieler JF, Lanoë JL, Amarenco P. Costs of stroke care according to handicap levels and stroke subtypes. *Cerebrovasc*

- Dis* 2004;**17**:134–42. DOI: 10.1159/000075782; PMID: 14707413
24. Leon MB, Smith CR, Mack M, et al. Transcatheter aortic-valve implantation for aortic stenosis in patients who cannot undergo surgery. *N Engl J Med* 2010;**363**:1597–607. DOI: 10.1056/NEJMoa1008232; PMID: 20961243
 25. Leon MB. Transcatheter or surgical aortic-valve replacement in intermediate-risk patients. *N Engl J Med* 2016;**374**:1609–20. DOI: 10.1056/NEJMoa1514616v; PMID: 27040324
 26. Smith CR, Leon MB, Mack MJ, et al. Transcatheter versus surgical aortic-valve replacement in high-risk patients. *N Engl J Med* 2011;**364**:2187–98. DOI: 10.1056/NEJMoa1103510; PMID: 21639811
 27. Popma JJ, Adams DH, Reardon MJ, et al. Transcatheter aortic valve replacement using a self-expanding bioprosthesis in patients with severe aortic stenosis at extreme risk for surgery. *J Am Coll Cardiol* 2014;**63**:1972–81. DOI: 10.1016/j.jacc.2014.02.556; PMID: 24657695
 28. Adams DH, Popma JJ, Reardon MJ, et al. Transcatheter aortic-valve replacement with a self-expanding prosthesis. *N Engl J Med* 2014;**370**:1790–8. DOI: 10.1056/NEJMoa1400590; PMID: 24678937
 29. Thourani VH, Kodali S, Makkar RR, et al. Transcatheter aortic valve replacement versus surgical valve replacement in intermediate-risk patients: a propensity score analysis. *Lancet* 2016;**387**:2218–25. DOI: 10.1016/S0140-6736(16)30073-3; PMID: 27053442
 30. Wendler O, Schymik G, Treede H, et al. SOURCE 3 registry: design and 30-day results of the European post approval registry of the latest generation of the Sapien 3TM transcatheter heart valve. *Circulation* 2017;**116**:025103. DOI: 10.1161/CIRCULATIONAHA.116.025103; PMID: 28104716
 31. Frerker C, Schluter M, Sanchez OD, et al. Cerebral protection during MitraClip implantation: initial experience at 2 centers. *JACC Cardiovasc Interv* 2016;**9**:171–9. DOI: 10.1016/j.jcin.2015.09.039; PMID: 26723763
 32. Meincke F, Spangenberg T, Kreidel F, et al. Rationale of cerebral protection devices in left atrial appendage occlusion. *Catheter Cardiovasc Interv* 2017;**89**:154–8. DOI: 10.1002/ccd.26677; PMID: 27762092
 33. Grover G, Rudarakanthana N, Perera A, et al. Cerebral embolic protection in thoracic aortic stent-grafting. ISET 2016. Available at: <http://claretmedical.com/pdf/studies/Grover%20ISET%202016%20TEVAR.pdf> (accessed 22 August 2017)
 34. Jánosi RA. Cerebral Protection against Embolization during Thoracic EndoVascular Aortic Repair. LINC 2016. Available at: http://claretmedical.com/pdf/studies/LINC_2016_Claret_Janosi_TEVAR.pdf (accessed 22 August 2017)
 35. Giustino G, Mehran R, Veltkamp R, Faggioni M, Baber U, Dangas GD. Cerebral embolic protection during TAVR: a clinical event meta-analysis. *J Am Coll Cardiol* 2017;**4**:463–70. DOI: 10.1016/j.jacc.2016.12.002; PMID: 28126163
 36. Wohrle J. Coronary and Structural Interventions Ulm – Transcatheter Aortic Valve Replacement (CSI-Ulm-TAVR) University of Ulm. German Society for Cardiology (DGK) 2017 (in press).
 37. Claret Medical. *Sentinel System Instructions for Use*. Santa Rosa, CA: Claret Medical, 2017.
 38. Giustino G, Mehran R, Veltkamp R, Faggioni M, Baber U, Dangas GD. Neurological outcomes with embolic protection devices in patients undergoing transcatheter aortic valve replacement: a systematic review and meta-analysis of randomized controlled trials. *JACC Cardiovasc Interv* 2016;**9**:2124–33. DOI: 10.1016/j.jcin.2016.07.024; PMID: 27765306
 39. Jensen CJ, Wolf A, Schmitz T, et al. Prevalence and etiopathology of thromboembolic debris during transcatheter interventional aortic valve replacement: results of the SENTINEL H-Study. *EuroPCR* 2016. Available at: www.pconline.com/eurointervention/AbstractsEuroPCR2016_issue/abstracts-europcr-2016/Euro16A-OP0439/prevalance-and-etio-pathology-of-thromboembolic-debris-during-transcatheter-interventional-aortic-valve-replacement-preliminary-results-of-the-sentinel-h-study.html (accessed 22 August 2017)