

**ORIGINAL STUDIES**

# Primary outcomes and mechanism of action of intravascular lithotripsy in calcified, femoropopliteal lesions: Results of Disrupt PAD II

Marianne Brodmann MD<sup>1</sup> | Martin Werner MD<sup>2</sup> | Andrew Holden MD<sup>3</sup> |  
 Gunnar Tepe MD<sup>4</sup> | Dierk Scheinert MD<sup>5</sup> | Arne Schwindt MD<sup>6</sup> | Florian Wolf MD<sup>7</sup> |  
 Michael Jaff DO<sup>8</sup> | Alexandra Lansky MD<sup>9,10,11</sup> | Thomas Zeller MD<sup>12</sup>

<sup>1</sup>Clinical Division of Angiology Department of Internal Medicine, Medical University Graz, Graz, Austria

<sup>2</sup>Hanusch Hospital Vienna, Vienna, Austria

<sup>3</sup>Auckland City Hospital, Auckland, New Zealand

<sup>4</sup>RoMed Klinikum, Rosenheim, Germany

<sup>5</sup>Park Krankenhaus, Leipzig, Germany

<sup>6</sup>St Franziskus Hospital, Muenster, Germany

<sup>7</sup>Medical University of Vienna, Vienna, Austria

<sup>8</sup>Newton-Wellesley Hospital, Newton, Massachusetts

<sup>9</sup>Yale University School of Medicine, New Haven, Connecticut

<sup>10</sup>BARTS Heart Center, London, United Kingdom

<sup>11</sup>The William Harvey Research Institute, Queen Mary University of London, London, United Kingdom

<sup>12</sup>Universitäts- Herzzentrum Freiburg, Bad Krozingen, Germany

**Correspondence**

Thomas Zeller, MD, Division of Angiology, Department of Internal Medicine, Universitäts-Herzzentrum Freiburg, Bad Krozingen, Klinik für Kardiologie und Angiologie II, Südring 15, 79189 Bad Krozingen, Germany. Email: thomas.zeller@universitaets-herzzentrum.de

**Funding information**

Shockwave Medical, Inc

**Abstract**

**Objective:** DISRUPT PAD II was designed to evaluate the safety and performance of intravascular lithotripsy (IVL), a novel approach using pulsatile sonic pressure waves, to modify intimal and medial calcium in stenotic peripheral arteries.

**Background:** Vascular calcification restricts vessel expansion, increases the risk of vascular complications, and may impair the effect of anti-proliferative therapy.

**Methods:** Disrupt PAD II was a non-randomized, multi-center study that enrolled 60 subjects with complex, calcified peripheral arterial stenosis at eight sites. Patients were treated with IVL and followed to 12-months. The primary safety endpoint was major adverse events (MAE) through 30 days. The primary effectiveness endpoint was patency at 12 months as adjudicated by duplex ultrasonography (DUS). Key secondary endpoints included acute procedure success, freedom from re-intervention, and functional outcomes.

**Results:** Between June 2015 and December 2015, subjects with moderate or severe calcified arterial lesions were enrolled. The final residual stenosis was 24.2%, with an average acute gain of 3.0 mm. The 30-day MAE rate was 1.7% with one grade D dissection that resolved following stent placement. Primary patency at 12 months was 54.5%, and clinically driven TLR at 12 months was 20.7%. Optimal IVL technique defined by correct balloon sizing and avoiding therapeutic miss, improved 12-month primary patency and TLR outcomes to 62.9% and 8.6%, respectively.

**Conclusions:** IVL demonstrated compelling safety with minimal vessel injury, and minimal use of adjunctive stents in a complex, difficult to treat population.

**KEYWORDS**

clinical trials, new devices, peripheral arterial disease, peripheral intervention

## 1 | INTRODUCTION

Calcified, femoropopliteal peripheral artery disease (PAD) adds to lesion complexity and represents a significant portion (21.0%) of revascularization procedures, frequently requiring a significant number of interventional devices to ensure long-term primary patency.<sup>1</sup> Risk factors associated with vascular calcification include advanced

age, diabetes mellitus, and chronic kidney disease.<sup>2,3</sup> Calcification restricts vessel expansion resulting in higher residual stenosis and lower procedural effectiveness and durability. Calcification may also impair the antiproliferative effect of drug coated balloons (DCB) by likely acting as a physical barrier to drug penetration itself.<sup>4,5</sup> In addition, calcification increases the risk of vascular complications following treatment including dissection, perforation, distal embolization, and

restenosis after percutaneous transluminal angioplasty (PTA) or stenting.<sup>6–10</sup> As a result, patients with severe calcification are usually excluded from contemporary peripheral arterial clinical trials.<sup>11–14</sup>

Atherectomy has been studied as a treatment option for calcified PAD in single-arm studies, primarily with acute results being reported. These studies have reported a reduction in final residual stenosis and reduced bail-out stenting. However, vascular complications including perforation and distal embolization remain an ongoing clinical concern.<sup>15–17</sup>

The first use of Intravascular Lithotripsy (IVL) in femoropopliteal arteries for modification of calcified plaque was recently described.<sup>18</sup> IVL leverages similar principles to urologic lithotripsy, which is an accepted safe and effective treatment of renal calculi. Electrohydraulic-generated sonic pressure waves pass through soft tissue and interact strongly with high-density calcium, producing significant shear stresses that fracture calcium. IVL is designed to modify both intimal and medial calcium across a wide range of vascular applications to increase vessel compliance, restore vessel mobility, and provide new versatile treatment options for patients. The Disrupt PAD II Study was designed to evaluate the safety and effectiveness of localized lithotripsy therapy of calcified obstructive femoropopliteal lesions using the Shockwave Medical Peripheral IVL System up to 12-month follow-up.

## 2 | MATERIALS AND METHODS

### 2.1 | Study design and patient enrollment

The Disrupt PAD II study was a prospective, non-randomized, multi-center study conducted to assess the safety and effectiveness of the Shockwave Peripheral IVL System for the treatment of calcified, stenotic, peripheral arteries. Patients were eligible for enrollment if they had claudication or rest pain, defined as Rutherford classification of 2–4, diameter stenosis  $\geq 70\%$ , target zone length  $\leq 150$  mm, reference vessel diameter of 3.5–7.0 mm, a minimum of one vessel run-off, and calcification as determined by the operators, that was on parallel sides of the vessel and  $\geq 50\%$  the lesion length.

The Ethics Committee for each site approved the study protocol and informed consent form, which was signed by all patients prior to study enrolment. The study was conducted in accordance with the Declaration of Helsinki, ISO 14155:2011 Guidelines, and Good Clinical Practices. An independent angiographic core laboratory analyzed all procedural angiograms using standard methods (Yale Cardiovascular Research Group, New Haven, CT, USA). Calcification was defined by the core lab as the presence of calcium on one (moderate) or both sides (severe) of the arterial wall. As calcification burden is defined differently across trials, a post hoc analysis using the PARC criteria was done by the core lab utilizing the prospectively collected angiograms.<sup>19</sup> An independent clinical events committee (CEC) adjudicated all major adverse events (MAE) and TLR (Yale Cardiovascular Research Group, New Haven, CT, USA). The study was registered on the National Institutes of Health website (ClinicalTrials.gov; identifier NCT02369848).

### 2.2 | Device description

The Shockwave Peripheral IVL system consists of a generator, a connector cable, and a single-use sterile disposable catheter that contains multiple lithotripsy emitters enclosed in an integrated balloon. The emitters positioned along the length of the balloon create a localized field effect via sonic pressure waves that selectively disrupt and fracture calcium in situ, altering vessel compliance, while minimizing injury and maintaining the integrity of the fibro-elastic components of the vessel wall (Supporting Information Figure, online only). The peripheral IVL System is indicated for lithotripsy-enhanced, low-pressure balloon dilatation of calcified, stenotic peripheral arteries in patients who are candidates for percutaneous therapy. The IVL device is available in eight sizes: diameter range of 3.5–7.0 mm in half millimeter increments all 60 mm in length.

### 2.3 | Study procedures

A patient was considered enrolled once the IVL catheter insertion was attempted. The IVL catheter diameter was sized 1:1 to the reference vessel diameter, the IVL balloon was inflated sub-nominally to 4 atm to ensure apposition to the arterial wall, and 30 pulses were delivered. Following lithotripsy, the IVL balloon was inflated nominally to 6 atm to match the reference vessel diameter. Additional lithotripsy pulses could be delivered to a target lesion using angiographic guidance to obtain an optimal reduction in diameter stenosis. Pre-dilatation with a small diameter, standard PTA catheter was allowed in the event the IVL catheter could not cross the lesion. Post-dilatation was allowed to ensure an optimal result, and provisional stenting was allowed to address severe dissection or high-grade residual stenosis. No drug-elution technologies including drug-coated balloon (DCB) or drug-eluting stent (DES) were allowed in the study protocol. Final angiography, including runoff views was performed to assess the final procedural result.

### 2.4 | Endpoints

The primary performance endpoint was target lesion patency at 12 months defined as freedom from  $\geq 50\%$  restenosis by DUS as adjudicated by an independent duplex ultrasonography core laboratory (VasCore, Massachusetts General Hospital, Boston, MA). The standard primary patency composite endpoint, as recommended by the PARC Consortium, was added during the course of the study to align with contemporary peripheral endovascular clinical study outcomes. Primary patency was defined as freedom from clinically-driven TLR and freedom from  $\geq 50\%$  restenosis as determined by DUS. The primary safety endpoint was MAE through 30 days defined as emergency surgical revascularization of the target limb, unplanned target limb major amputation, symptomatic thrombus or distal emboli, and perforations or Grade D or greater dissections requiring an intervention.

Secondary endpoints included acute procedural success, safety, effectiveness and functional outcomes. Acute procedural success was defined as the ability of the IVL catheter to achieve a post-IVL residual stenosis of  $< 50\%$ . The secondary safety endpoint was freedom from MAEs at 12 months. Secondary effectiveness outcomes included target lesion patency at 30 days and 6 months, and TLR at 12 months. Functional outcomes included improvement in ankle-brachial index (ABI) and Rutherford Classification at 30 days, 6 months, and 12 months.

**TABLE 1** Baseline characteristics

Clinical characteristics	N = 60
Age, years, mean $\pm$ SD	71.5 $\pm$ 8.3
Male gender, % (n)	78.3% (47)
Diabetes, % (n)	56.7% (34)
Hypertension, % (n)	96.7% (58)
Hyperlipidemia, % (n)	80.0% (48)
Renal insufficiency, % (n)	28.3% (17)
Coronary artery disease, % (n)	51.7% (31)
Current or former smoker, % (n)	81.7% (49)
Rutherford class, % (n)	
RC 2	30% (18)
RC 3	70% (42)
RC 4	0% (0)
Pre-angiographic characteristics	
SFA, % (n)	73.3% (44)
Popliteal, % (n)	26.7% (24)
Reference vessel diameter, mm, mean $\pm$ SD	5.4 $\pm$ 0.8
Mean luminal diameter, mm, mean $\pm$ SD	1.1 $\pm$ 0.7
Diameter stenosis, %, mean $\pm$ SD	78.2 $\pm$ 13.5
CTO, % (n)	16.7% (10)
Lesion length, mm, mean $\pm$ SD	76.9 $\pm$ 34.8
Calcified length, mm, mean $\pm$ SD	98.1 $\pm$ 41.7
Calcification by original core lab definition <sup>a</sup> , % (n)	
Moderate	48.3% (29)
Severe	50.0% (30)
Calcification by PARC definition <sup>b</sup> , % (n)	
Moderate	8.3% (5)
Severe	85.0% (51)

<sup>a</sup> Moderate defined as densities noted only prior to contrast injection, and severe as radiopacities noted prior to contrast injection generally involving both sides of the arterial wall.

<sup>b</sup> Moderate defined as  $\geq 180$  (both sides of vessel at same location) and less than one-half of the total lesion length, and severe defined as  $\geq 180$  both sides of the vessel at the same location) and greater than one-half of the total lesion length.

## 2.5 | Statistics

The study was designed to enroll 60 subjects to provide benchmark estimates of the primary and secondary endpoints. No formal hypothesis testing was used to derive the sample size. The mean and 95% confidence intervals were reported for MAE at 30 days and for target lesion patency at 12 months. Categorical data were summarized using frequency tables, presenting the subject counts and percentages. Continuous variables were summarized by the mean, standard deviation, median, minimum and maximum. All analyses were intention-to-treat. Statistical analyses were carried out using SAS (SAS Institute, Cary, NC) version 9.2 or higher.

## 3 | RESULTS

### 3.1 | Enrollment and baseline characteristics

Between June 2015 and December 2015, a total of 60 subjects were enrolled at eight clinical sites in Austria, Germany and New Zealand. Baseline characteristics represent a complex patient population with marked lesion calcification and are summarized in Table 1. The average lesion length was 76.9 mm, 26.7% of the lesions were in the

popliteal artery and 16.7% represented chronic total occlusions. Calcium burden was significant with severe calcification involving both sides of the arterial wall seen by the core lab in 50% of the subjects, with an average length of calcium of 98.1 mm. Calcium length was determined by the proximal and distal calcium edges which may exceed the length of the targeted lesion. Severe calcification by the PARC definition was identified in 85.0% of subjects.<sup>19</sup>

### 3.2 | Procedural outcomes

All 60 subjects had successful IVL catheter delivery and received lithotripsy treatment. The mean number of pulses was 136, at a mean IVL inflation pressure of 6.5 atm. (Table 2) Adjunctive therapies were infrequent, including 13.3% pre-dilatation, 3.3% post-dilatation, 3.3% embolic protection filters, and stent placement in only one subject (1.7%). The final residual stenosis was 24.2%, with an average acute gain of 3.0 mm. Angiographic complications included a single grade D dissection that was guidewire induced through recanalization of a CTO which was resolved with stent placement; there was no abrupt closure, no-reflow, distal embolization, or perforation events. Angiographic results are summarized in Table 2.

### 3.3 | Effectiveness outcomes

The primary performance endpoint of target lesion patency by DUS was 69.8% at 12 months. Primary patency at 12 months, defined as freedom from clinically-driven TLR and from  $\geq 50\%$

**TABLE 2** Procedural outcomes

Procedural details	N = 60
Procedure duration, minutes, mean $\pm$ SD	71.1 $\pm$ 32.2
Fluoroscopy time, minutes, mean $\pm$ SD	14.9 $\pm$ 11.6
Contrast, ml, mean $\pm$ SD	106.8 $\pm$ 44.2
Embolic protection device, % (n)	3.3% (2)
Pre-dilatation, % (n)	13.3% (8)
Successful IVL delivery, % (n)	100% (60)
IVL pulses, mean $\pm$ SD	136 $\pm$ 75.0
Mean pressure, mmHg, mean $\pm$ SD	6.5 $\pm$ 1.5
Post-dilatation, % (n)	3.3% (2)
Stents, % (n)	1.7% (1)
Post-angiographic characteristics	
Mean luminal diameter, mm, mean $\pm$ SD	4.2 $\pm$ 0.6
Diameter stenosis, %, mean $\pm$ SD	24.2 $\pm$ 5.7
Acute gain, mm, mean $\pm$ SD	3.0 $\pm$ 0.8
Dissection, % (n)	
None	86.7% (51)
A	0.0%
B	6.7% (4)
C	6.7% (4)
D	1.7% (1)
Perforation, % (n)	0% (0)
Distal embolization, % (n)	0% (0)
Thrombus, % (n)	0% (0)
No reflow, % (n)	0% (0)
Abrupt closure, % (n)	0% (0)

**TABLE 3** Results

	30 days	6 months	12 months
<b>Performance results</b>			
Target lesion patency <sup>a</sup>	100% (56/56)	72.7% (40/55)	69.8% (30/43)
Freedom from TLR <sup>b</sup>	100% (58/58)	98.3% (57/58)	79.3% (46/58)
Primary patency <sup>c</sup>	100% (56/56)	71.4% (40/56)	54.5% (30/55)
<b>Safety results<sup>c</sup></b>			
Major adverse events (MAE)	1.7% (1/59)	1.7% (1/58)	1.8% (1/57)
Emergency surgical revascularization of target limb	0% (0/59)	0% (0/58)	0% (0/57)
Unplanned target limb amputation	0% (0/59)	0% (0/58)	0% (0/57)
Symptomatic thrombus or emboli	0% (0/59)	0% (0/58)	0% (0/57)
Perforations or Gr D dissections w/ interventions	1.7% (1/59)	1.7% (1/58)	1.8% (1/57)

<sup>a</sup> Excludes any patient that had a TLR from analysis.

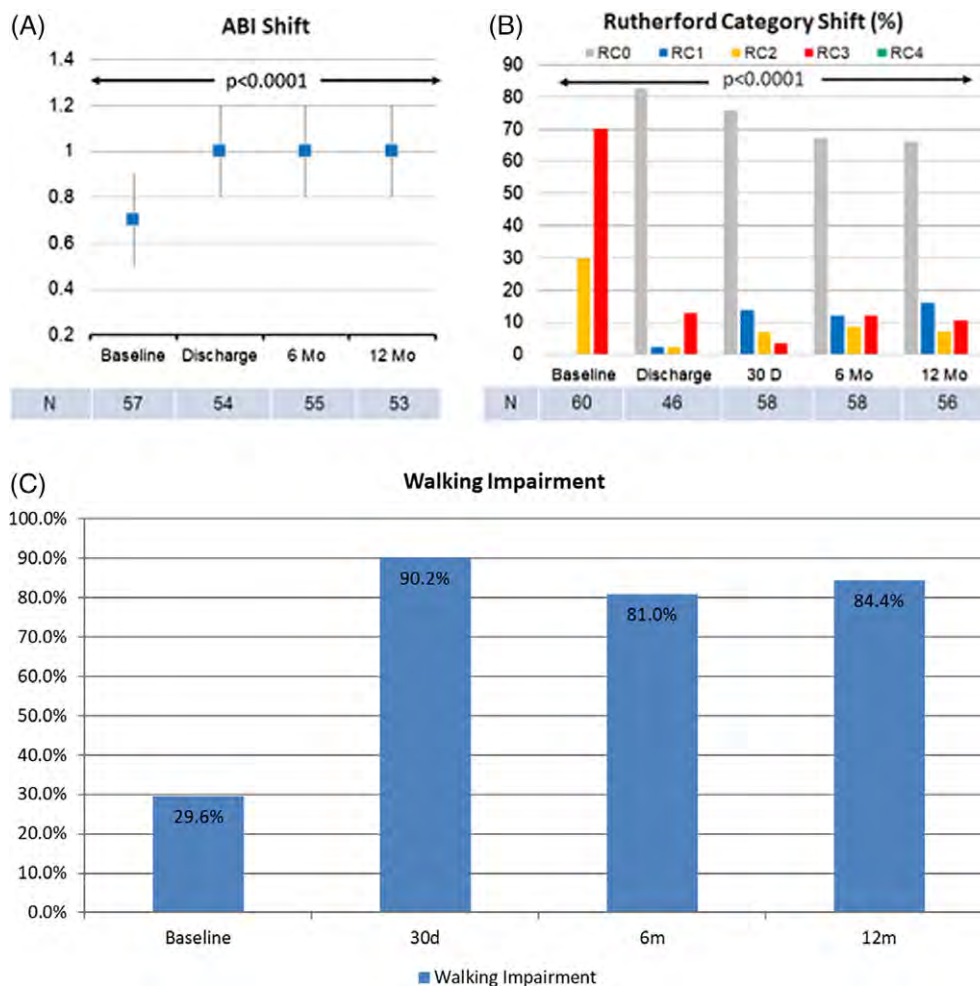
<sup>b</sup> Two patients withdrew from the study.

<sup>c</sup> Three patients did not complete DUS, 2 patients withdrew from the study.

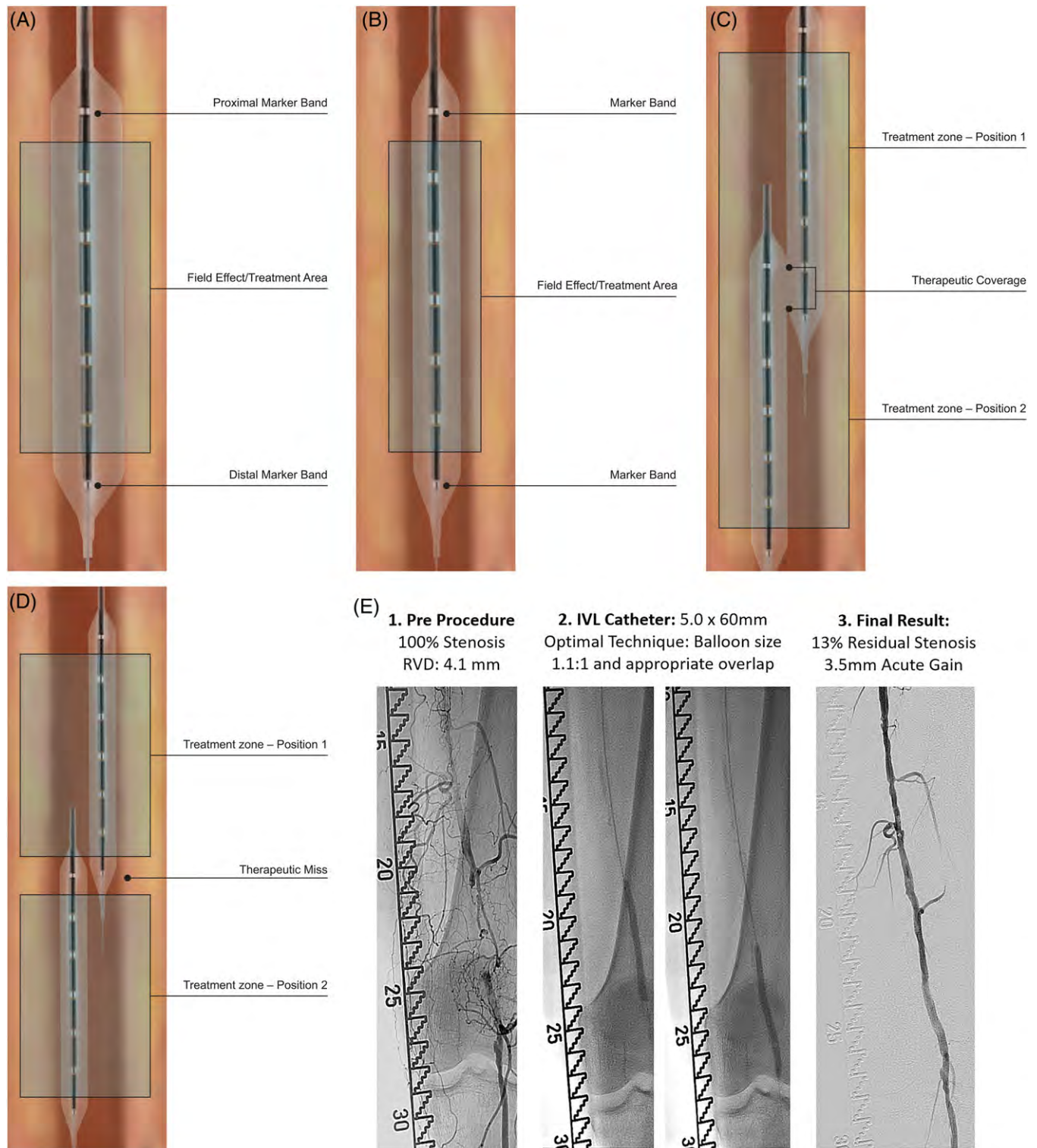
stenosis by duplex ultrasound, was 54.5%, and clinically-driven TLR at 12 months was 20.7%. Twelve patients underwent a percutaneous target lesion revascularization within the 12-month follow-up. The core lab assessed the patterns of restenosis, and identified two as focal, eight as diffuse, and two complete occlusions. All TLR's were performed via an endovascular approach (Table 3).

### 3.4 | Safety outcomes

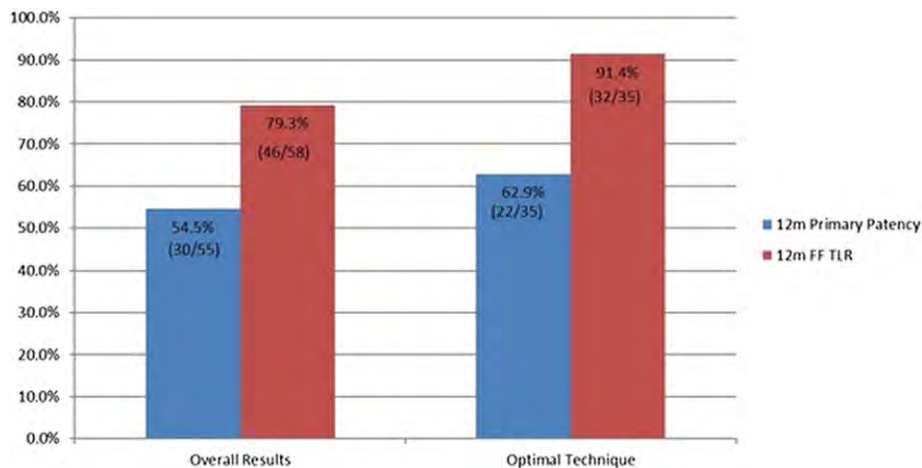
The MAE rate at 30 days was 1.7%. There were no emergency surgical revascularizations, unplanned target limb amputations, symptomatic thrombus or embolization, or perforations. No additional MAEs occurred beyond 30 days. There was one death during the study, adjudicated as cardiac related, and not related to the study device or procedure by the CEC (Table 3).



**FIGURE 1** Demonstrates a significant and sustained improvement in functional outcomes at all time intervals in both ABI Shift (A), Rutherford Category (B) and Walking Impairment (C)



**FIGURE 2** A. Illustrates the IVL catheter placed into the target lesion, with good wall apposition (balloon 1.1:1 to RVD) and full circumferential field effect in the vessel wall; B. Illustrates the IVL catheter placed into the target lesion, undersized balloon, minimizing the circumferential field effect into the vessel wall; C. Illustrates the IVL catheter repositioned with a long target lesion, with full therapeutic coverage. The second position overlaps the distal marker band with the proximal marker band by 1cm, providing lithotripsy to entire target segment; D. Illustrates the IVL catheter repositioned within a long target lesion with a therapeutic coverage miss. The marker bands are aligned creating a gap in therapy between the two treatment zones; E. Case example with optimized technique 1. Pre-procedure angiography: Popliteal lesion with vessel diameter of 4.1 mm, stenosis of 100% 2. Treatment with 5.0 mm x 60 mm IVL catheter, Optimal technique with balloon sizing 1.1:1 and complete therapeutic coverage (appropriate overlap). 3. Residual stenosis of 13% and acute gain of 3.5mm



**FIGURE 3** Optimal IVL technique was associated with significant improvement in clinical patency. Primary patency by DUS at 12-months was 54.5% (35/55) for intent-to-treat versus 62.9% (22/35) for those with optimal technique. Clinically-driven TLR at 12-months was 20.7% for intent-to-treat versus 8.6% for those with optimal technique. Optimal technique was defined as correct balloon sizing and avoidance of therapeutic miss

### 3.5 | Clinical outcomes

Improvement in ABI was statistically significant at each post-procedure interval indicating a sustained hemodynamic benefit. Improvement in Rutherford Category was also statistically significant at each post-procedure interval, indicating improved symptoms related to intermittent claudication. Additionally, improvements in subject-reported WIQ results were statistically significant at all time points in all walking domains including impairment, distance, speed, and stairs (Figure 1).

### 3.6 | Sub-group analysis based on optimal IVL technique

A post hoc analysis was completed by the core lab, using the prospectively collected data, to assess optimal device technique. Optimal technique was defined as correct balloon sizing and avoidance of therapeutic miss (Figure 2). Balloon sizing was calculated as the ratio of the IVL balloon to the reference vessel diameter by QVA. An IVL balloon to RVD ratio  $\geq 1$  defined correct balloon sizing. The IVL balloon was undersized in 13 subjects. Therapeutic miss was defined as failure to provide full lithotripsy at an overlap segment or at the proximal or distal lesion location (Figure 2). Therapeutic miss occurred in 10 subjects. Optimal IVL technique was associated with a significant improvement in patency. Primary patency by DUS at 12-months was 54.5% (35/55) for intent-to-treat versus 62.9% (22/35) for those with optimal technique (Figure 3). More importantly, clinically-driven TLR at 12-months was 20.7% for intent-to-treat versus 8.6% for those with optimal technique. Oversizing the IVL catheter did not have a negative impact on primary patency or result in an increased risk for dissection.

## 4 | DISCUSSION

This is the first safety and performance report of a stand-alone, novel intravascular lithotripsy system for modification of calcified

femoropopliteal lesions with mid-term follow-up. We demonstrate in a highly complex patient population, with severely calcified SFA and popliteal lesions typically excluded from contemporary peripheral studies that use of the IVL device: (i) is safe and feasible (ii) achieves high procedure success using low IVL inflation pressures and minimal adjunctive PTA and stents, and (iii) optimal technique with at least 1:1 IVL balloon to artery sizing and adequate therapeutic coverage, improves 12 month primary patency, resulting in a clinically-driven TLR rate of 8.6%.

The Disrupt PAD II Study enrolled a difficult to treat calcified arterial population. IVL treatment resulted in a high acute luminal gain ( $3.0 \pm 0.8$  mm), with a low average balloon inflation pressure of 6.5 atm, despite severe artery calcification in 85.0% of the patients by the PARC criteria. Vascular complications were minimal with a single Grade D dissection reported that resulted in the only stent implant. Traditional PTA of complex peripheral lesions, whether with or without drug-elution, has historically required a significant number of bail-out stents (11.0–40.3%) for high-grade residual stenosis or flow-limiting dissections at the time of procedure.<sup>5,20</sup> Key procedural safety complications including perforation, slow flow, and distal embolization were reported in the atherectomy studies and did not occur following treatment with IVL.<sup>15,21</sup> The 12-month intent-to-treat primary patency results with stand-alone IVL are comparable to what has been seen in limited series with drug-coated balloons in calcified patients.<sup>4,14</sup>

This study provided insights into the mechanism of action of intravascular lithotripsy in the clinical setting. Lithotripsy improved vessel compliance, as evidenced by balloon expansion during sonic pulsing while maintaining low pressure inflations. This result suggests both intimal and medial calcium are impacted by IVL. A recently published sub-study of the Disrupt-CAD utilizing high resolution optical coherence tomography (OCT) imaging confirmed the mechanisms of action. Circumferential calcium fractures were identified that resulted in vessel expansion, including the maximal areas of calcification.<sup>22</sup> These findings are further supported by a single center, core lab adjudicated, OCT sub-study of Disrupt PAD II in calcified femoropopliteal arteries.<sup>23</sup> The OCT results demonstrated luminal gain and changes in

vessel compliance across all levels of calcium thickness via controlled micro-fractures and micro-dissections. Additionally, distal embolic filters were used at the discretion of the investigator in only two cases, and no embolic debris was present. This is consistent with the initial experience of peripheral IVL,<sup>18</sup> suggesting a low risk of distal embolization.

Optimal technique has long lasting, clear benefit with response to 12-month clinically-driven TLR, improving primary patency to 62.9% and clinically driven TLR of 8.6%. We identified variability in technical use with respect to balloon sizing and therapeutic coverage that impacted primary patency and TLR results. Experience with the technology highlighted the importance of correct balloon sizing which is crucial to ensure appropriate long-term primary patency outcomes. Lithotripsy is delivered through the IVL catheter at a sub-nominal pressure of 4 atm. Appropriate IVL balloon catheter apposition to the arterial wall is needed to facilitate lithotripsy from the emitter on the catheter, through the aqueous solution in the balloon, to the arterial wall to modify calcified plaques. Sizing the IVL catheter at or above the reference vessel diameter resulted in a significant improvement in patency at 12 months compared with those who were undersized. We also learned that sizing the IVL catheter more than 10% above the reference diameter did not have a detrimental impact on patency or dissections. As a result of these findings, the instructions for use have been revised to instruct physicians to size the IVL catheter 1.1:1 to the vessel diameter. Given the IVL catheter is supplied in 0.5 mm diameter increments, a physician should use an IVL catheter that is 0.5 mm larger than the diameter to ensure long term results.

The second technical lesson involved therapeutic coverage of lithotripsy both circumferentially and longitudinally within a target lesion. This peripheral IVL catheter has five lithotripsy emitters enclosed on an integrated balloon. When activated, the lithotripsy emitters create sonic pressure waves with a circumferential field effect to disrupt calcified lesions. Since IVL is non-focused lithotripsy the field effect drops significantly as the distance from the emitter increases. We learned the field effect drops longitudinally outside the most proximal and distal emitters. In the event a single IVL catheter is used to treat a long lesion appropriate balloon overlap between segments is needed to ensure appropriate therapeutic coverage of lithotripsy within the target lesion. As a result of these findings, the instructions for use have also been revised to instruct physicians to overlap the IVL catheter a minimum of 1 cm in overlapping segments and at the proximal and distal target lesion to ensure appropriate therapeutic coverage. See Figure 2.

Those treated with IVL as a stand-alone treatment in calcified disease experienced similar improvements in clinical outcomes at 12-months as those treated with other endovascular interventions, such as DCB and atherectomy.<sup>4,24</sup> Revascularizations were completed with simple endovascular procedures, and did not result in a need for bypass surgery or recurrent occlusions as has been seen following stenting in TASC C and D lesions.<sup>25</sup>

#### 4.1 | Limitations

Our study has several limitations. First, the present study is a single-arm study without a control group which may have an impact on the

reported subjective outcomes. Second, Disrupt PAD II did not allow concomitant treatment with drug-elution either with a peripheral DCB or DES. Third, the mechanisms of action learnings were the result of post hoc analyses based on pre-specified core lab analyses. Last, there is no consistent definition for calcification, which makes cross study comparison of results difficult to make.

The Disrupt PAD III study is a currently enrolling randomized controlled study. The objective is to assess the optimal therapy to dilate heavily calcified lesions with IVL versus PTA. Patients who do not receive a bail-out stent will be treated with a DCB. Lessons learned from the Disrupt PAD II Study will be further assessed in PAD III to understand the mechanism of action of IVL.

## 5 | CONCLUSION

In conclusion, use of intravascular lithotripsy as a standalone therapy, is safe and effective in a patient population that has historically been excluded from studies. Treatment with IVL is associated with minimal vascular complications, a large acute gain, and minimal use of stent implants. IVL technique can be optimized to improve patency at 12 months and can be easily adopted by peripheral interventionalists.

### ACKNOWLEDGMENTS

The authors thank Beaux Alexander, MBA and Suzanne Wallace, MSN, CRNP of Shockwave Medical for support in manuscript preparation.

### CONFLICT OF INTEREST

Drs. Brodmann, Werner, Holden, Tepe, Scheinert, Schwindt, Wolf, Lanksy and Zeller received institutional grants for the Disrupt PAD Study. Dr. Jaff has no disclosures. Drs. Brodmann, Holden, and Zeller have participated in Physician advisory meetings for Shockwave Medical with less than \$10,000 of personal compensation.

### ORCID

Marianne Brodmann  <https://orcid.org/0000-0001-6493-3799>

Alexandra Lansky  <https://orcid.org/0000-0001-8002-7497>

### REFERENCES

- Walker K, Nolan B, Columbo JA, et al. Lesion complexity drives the cost of superficial femoral artery endovascular interventions. *J Vasc Surg.* 2015;62(4):998-1002.
- Rocha-Singh KJ, Zeller T, Jaff MR. Peripheral arterial calcification: Prevalence, mechanism, detection and clinical implications. *Catheter Cardiovasc Interv.* 2014;83:E212-E220.
- Lanzer P, Böhm M, Sorribas V, et al. Medial vascular calcification revisited: Review and perspectives. *EHJ.* 2014;35:1515-1525.
- Fanelli F, Cannavale A, Gazzetti M, et al. Calcium burden assessment and impact on drug-eluting balloons in peripheral arterial disease. *Cardiovasc Intervent Radiol.* 2014;37:898-907.
- Tepe G, Beschoner U, Ruether C, et al. Predictors of outcomes of drug-eluting balloon therapy for femoropopliteal arterial disease with a special emphasis on calcium. *J Endovasc Ther.* 2015;22(5):727-733.
- Freed MS, Safian RD. *Manual of Interventional Cardiology.* Baltimore, MD: Jones & Bartlett Publishers; 2001.

7. Kawaguchi R, Tsurugaya H, Hoshizaki H, Toyama T, Oshima S, Taniguchi K. Impact of lesion calcification on clinical and angiographic outcome after sirolimus-eluting stent implantation in real-world patients. *Cardiovasc Revasc Med*. 2008;9:2-8.
8. Mintz G, Popma J, Pichard A, et al. Patterns of calcification in coronary artery disease. *Circulation*. 1995;91:1959-1965.
9. Lee M, Canan T, Rha S, Mustaoha J, Adams G. Pooled analysis of the CONFIRM registries: Impact of gender on procedure and angiographic outcomes in patients undergoing orbital atherectomy for peripheral artery disease. *J Endovasc Ther*. 2015;22(1):57-62.
10. Babaev A, Zavulunova S, Attubato MJ, Martinsen BJ, Mintz GS, Maehara A. Orbital atherectomy plaque modification assessment of the femoropopliteal artery via intravascular ultrasound (TRUTH study). *Vasc Endovasc Surg*. 2015;49(7):188-194.
11. Rosenfield K, Jaff M, White CJ, et al. Trial of a paclitaxel-coated balloon for femoropopliteal artery disease. *NEJM*. 2015;373(2):145-153. <https://doi.org/10.1056/NEJMoa1406235>.
12. Jaff M. Drug-Coated balloon treatment for patients with intermittent claudication: Insights from the IN.PACT Global full clinical cohort. Presentation, VIVA, Las Vegas, Nevada, United States, 2016.
13. Krishnan P, Faries P, Niazi K, et al. Stellerex drug-coated balloon for treatment of Femoropopliteal disease. *Circulation*. 2017;136:1102-1113.
14. Tepe G, Laird J, Schnieder, et al. Drug-coated balloon versus standard percutaneous transluminal angioplasty for treatment of superficial femoral and popliteal peripheral artery disease. 12 month results from IN.PACT SFA randomized trial. *Circulation*. 2015;131:495-502.
15. Roberts D, Niazi K, Miller W, et al. Effective endovascular treatment of calcified Femoropopliteal disease with directional Atherectomy and distal embolic protection: Final results of the DEFINITIVE Ca11 trial. *Catheter Cardiovasc Intervent*. 2014;84:236-244.
16. Adams G, Das T, Lee M, Beasley R, Mustapha J. Subanalysis of the CONFIRM registries: Acute procedural outcomes in Claudicant and critical limb ischemia patients with varying levels of calcification treated for peripheral arterial disease with orbital atherectomy. *J Invasive Cardiol*. 2015;27(11):516-520.
17. McKinsey JF, Zeller T, Rocha-Singh KJ, Jaff MR, Garcia LA, on behalf of the DEFINITIVE LE Investigators. Lower extremity revascularization using directional atherectomy: 12 month prospective results of the DEFINITIVE LE study. *JACC Cardiovasc Interv*. 2014;8:923-933.
18. Brodmann M, Werner M, Britton T, et al. Safety and performance of Lithoplasty for treatment of calcified peripheral artery lesions. *JACC-Lett*. 2017;70(7):908-909.
19. Patel M, Conte M, Cutlip D, et al. Evaluation and treatment of patients with lower extremity peripheral artery disease: Consensus definition from peripheral academic research consortium (PARC). *J Am Coll Cardiol*. 2015;65(9):931-941.
20. Laird J, Katzen B, Scheinert D, et al. Nitinol stent implantation versus balloon angioplasty for lesions in the superficial femoral artery and proximal popliteal artery: Twelve-month results from the RESILIENT randomized trial. *Circ Cardiovasc Interv*. 2010;3(3):267-276.
21. Maehara A, Mintz G, Shimshak T, et al. Intravascular ultrasound evaluation of JETSTREAM atherectomy removal of superficial calcium in peripheral arteries. *EuroIntervention*. 2015;11:96-103.
22. Ali Z, Brinton T, Hill J, et al. Optical coherence tomography characterization of coronary lithoplasty for treatment of calcified lesions: First description. *J Am Coll Cardiol Img*. 2017;10(8):897-906.
23. Holden, A. Shockwave Intravascular Lithotripsy System Treatment of Calcified Lesions: Intravascular OCT Analysis. Presentation, LINC 2018, Leipzig, Germany.
24. Zeller T, Langhoff R, Rocha-Singh K, et al. Directional Atherectomy followed by a paclitaxel-coated balloon to inhibit restenosis and maintain vessel patency: Twelve-month results of the DEFINITIVE AR study. *Circ Cardiovasc Intervent*. 2017;10(9):e004848.
25. Tosaka A, Soga Y, Iida O, et al. Classification and clinical impact of restenosis after femoropopliteal stenting. *JACC*. 2012;59(1):16-23.

#### SUPPORTING INFORMATION

Additional supporting information may be found online in the Supporting Information section at the end of the article.

**How to cite this article:** Brodmann M, Werner M, Holden A, et al. Primary outcomes and mechanism of action of intravascular lithotripsy in calcified, femoropopliteal lesions: Results of Disrupt PAD II. *Catheter Cardiovasc Interv*. 2018;1-8. <https://doi.org/10.1002/ccd.27943>